

Professional Dancer's Hip: A Motion Capture Study

+¹Charbonnier, C; ²Kolo, F C; ³Duthon, V B; ¹Magenat-Thalmann, N; ²Becker, C; ³Hoffmeyer, P; ³Menetrey, J

+¹MIRALab, University of Geneva, Geneva, Switzerland, ²Department of Radiology, University Hospital of Geneva, Geneva, Switzerland, ³Department of Orthopaedic Surgery, University Hospital of Geneva, Geneva, Switzerland, charbonnier@miralab.unige.ch

INTRODUCTION

Professional ballet dancers present a higher risk of developing hip osteoarthritis (OA) due to repetitive and extreme movements performed during their daily activities [1]. Early OA could be explained by femoroacetabular impingements (FAI) that occur when there is an abutment conflict between the proximal femur and the acetabular rim [2]. However, the concurrence of the actual impingement zone and resulting joint damage in the same patient has not yet been confirmed. There is a lack of validated non-invasive methods and dynamic studies to ascertain FAI during motion. It is also unknown if the femoral head and acetabulum are congruent in extreme positions (e.g., split position). Joint congruency could be another potential cause of early OA.

Our hypothesis is that the practice of some dancing movements could expose the dancer's hip to a loss of joint congruence and to recurrent FAI, which could lead to early OA. The purpose of this research is to visualize and simulate in 3D extreme ranges of motion of the hip and to detect and locate potential FAI, using optical motion capture and computer-assisted techniques. Moreover, this study aims at quantifying in-vivo the range of motion (ROM) and congruence of the hip joint in typical dancing positions.

METHODS

Motion capture of the hip joint was carried out in 10 female professional ballet dancers (20 hips) aged between 17 and 37 years (mean, 23.8 years). The study was approved by the local ethics committee and the volunteers gave written informed consent. Data from the subjects were acquired during 6 dancing movements: grand plié, développé à la seconde, développé devant, grand écart latéral, grand écart facial and arabesque. The hip joint kinematics was computed from the recorded markers trajectories, using a validated optimized fitting algorithm which accounted for skin motion artifacts [3]. The resulting computed motions were applied to patient-specific hip joint 3D models reconstructed from MRI data (Fig. 1a). While visualizing the dancer's hip joint in motion, a collision detection algorithm [4] was used to virtually locate abnormal contacts between the femur and the labrum. Moreover, the surface-to-surface distance (i.e., penetration depth) was computed in order to estimate the overall FAI (Fig.1b). This distance represented the topographic extent of the labrum compression.

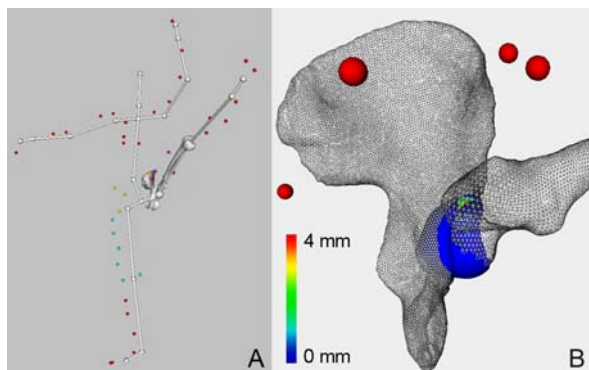


Figure 1: A) Example of computed dancing posture (développé à la seconde) B) Visualization of the FAI region during extreme motion (posterior view). The colors represent the penetration depth distribution.

The ROM and congruence of the hip joint were also quantified in those 6 recorded dancing movements. Thanks to two bone coordinate systems (one for the femur and one for the pelvis), normalized hip joint angles were determined at each point of the motion given the computed bone poses from motion capture data. The relative position between the hip bone and femur was described by making reference to a vector joining a point (i.e., the hip joint center) defined in each of the pelvic and the femoral frames.

For the 6 dancing movements, we calculated the frequency of impingement, subluxation and distribution of the zone of FAI. We

computed the mean values and the standard deviations (SD) of the penetration depth, subluxation and ROM according to the 3 standard medical angles. We finally compared the computed locations of impingement with radiologically diagnosed damaged zones in the labrum within the same subject.

RESULTS

Dancing involves intensive hip flexion and abduction combined with rotation. The mean \pm SD for flex/ext, abd/add and IR/ER was $84.44 \pm 22.76/31.60 \pm 7.95$, $42.42 \pm 20.49/0$ and $25.49 \pm 11.83/15.59 \pm 11.57$, respectively. The frequency of FAI and subluxation, and the amount of femoroacetabular translations and penetration depth varied with the type of movement (Table 1). Four dancing movements (développé à la seconde, grand écart facial, grand écart latéral and grand plié) seemed to create significant stress in the hip joint, according to the observed high frequency of impingement and amount of subluxation. 92% of the computed zones of FAI were located in the superior or posterosuperior part of the acetabulum. For more than 80% of the dancers' hips, the degenerative labral lesions were diagnosed in superior (69%) and posterosuperior positions (13%), and this was significantly correlated to individual computed impingement zones. Eventually, all the dancers' hips were morphologically normal, according to radiological experts.

Movements	Freq. of FAI	Freq. of subluxation	Penetration depth (mm)	Subluxation (mm)
Arabesque	0%	0%	0	0
Développé devant	27%	0%	2.5 ± 1.2	0
Développé à la seconde	44%	22%	3.38 ± 2.0	4.32 ± 1.17
Grand écart facial	63%	38%	3.87 ± 2.55	3.05 ± 1.38
Grand écart latéral (front leg)	73%	27%	2.07 ± 1.9	5.0 ± 1.54
Grand écart lateral (back leg)	25%	13%	1.11 ± 1.33	3.15 ± 0
Grand plié	44%	13%	2.58 ± 1.88	3.02 ± 2.28

Table 1: Frequency of impingement and subluxation, and amount (mean \pm SD) of penetration depth and subluxation by movement.

DISCUSSION

With the use of motion capture, FAI and joint congruency were actively assessed and demonstrated in-vivo. As expected, extreme motions are possible thanks to a combination of three articular motion patterns. FAI and subluxation were often observed in typical ballet positions. These movements should be hence limited in frequency. The computed zones of FAI were mainly located in the superior or posterosuperior area of the acetabulum and this was correlated with the MRI findings. This is unusual because resulting chondrolabral damages due to FAI such as of the cam or pincer type are generally located in the anterosuperior position. Consequently, we think that dancing implies a new superior/posterosuperior FAI. We also believe that FAI and subluxation could lead to cartilage hyperpression and therefore to early OA. Ongoing work involves physically-based simulations of the chondrolabral structures to account for their mechanical properties and deformations under stress.

REFERENCES 1. Lewis, CR et al., Acetabular labral tears, *Phys Ther*, 86:110-121, 2006. 2. Ganz, R et al., Femoroacetabular impingement: a cause for osteoarthritis of the hip, *Clin Orthop Relat Res*, 417:112-120, 2003. 3. Charbonnier, C et al., Motion study of the hip joint in extreme postures, *Vis Comput*, 25(9):873-882, 2009. 4. Charbonnier, C et al., Virtual Hip Joint: from Computer Graphics to Computer-Assisted Diagnosis, *Eurographics 2009*, pp. 1-4, 2009.