

THE SHOULDER IN TENNIS: THE DIFFERENT TYPES OF IMPINGEMENT & INSTABILITY

A. LÄDERMANN, N BONNEVIALLE, C. CHARBONNIER

INTRODUCTION

Shoulder pain and injury are common in tennis players, with a prevalence of 50% for certain categories of age [1]. A majority of the shoulder pains is caused by impingement and instability due to repetitive lifting and overhead arm movements [2, 3]. Two types of impingement have been distinguished: external and internal. External types include subacromial impingement of the rotator cuff between the anterior acromion [4] or lateral acromion [5, 6] and the superior humeral head that could occur with serves and overhead shots. Another type of external impingement is the less common subcoracoid impingement [7-9] of the subscapularis or biceps tendon. It results from contact between the coracoid process against the lesser tuberosity of the humeral head and is more likely to occur at the backhand preparation phase and the late follow-through phase of forehand. Internal impingement consists of *1)* posterosuperior impingement [10] of the supraspinatus and infraspinatus tendons between the greater tuberosity of the

humeral head and the posterosuperior aspect of the glenoid when the arm is in extreme abduction, extension and external rotation during the late cocking stage of the serve; and *2)* anterosuperior impingement [11, 12] of the deep surface of the subscapularis tendon and the reflection pulley on the anterosuperior glenoid rim that could also occur at the backhand preparation phase and the late follow-through phase of forehand.

The precise causes for these impingements remain unclear, but it is believed that repetitive contact, (**fig. 1A and 1B**) [10, 13] glenohumeral instability (**fig. 1C**) [13-15] scapular orientation, [16, 17] rotator cuff dysfunctions, [2, 3] posteroinferior capsular contracture with resultant glenohumeral internal rotation deficit (GIRD) [18] may play a role in the development of symptomatic impingement.

Measuring the dynamic *in-vivo* shoulder kinematics seems crucial to better understand numerous pathologies and to propose an adequate treatment. Indeed, a patient with an internal impingement will be treated differently if the etiology is a

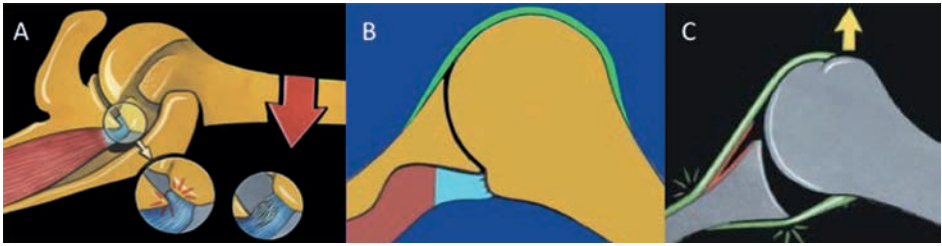


Fig. 1 : A) Gilles Walch's theory: the deep layer of the posterosuperior rotator cuff impinged with the posterior labrum and glenoid. B) Christopher Jobe's theory: the impingement is mainly due to hyperextension of the humerus relative to the scapula. C) Frank Jobe's theory: lesions in throwing athletes are related to subtle anterior instability.

posteroinferior capsular contracture with resultant GIRD (that respond generally positively to a compliant posteroinferior capsular stretching program or to an arthroscopic selective posteroinferior capsulotomy and concomitant SLAP lesion repair) [18] or a repetitive contact of the undersurface of the rotator cuff on the posterosuperior glenoid labrum (that can respond to debridement, glenoidplasty or derotational humeral osteotomy) [19-21]. However, such kinematic measurement remains a challenging problem due to the complicated anatomy and large range of motion of the shoulder. To our knowledge, impingements at critical tennis positions and glenohumeral stability have never been dynamically evaluated. Unfortunately, the motion of the shoulder cannot be explored with standard Magnetic Resonance Imaging (MRI) or Computed Tomography (CT) because they are limited to static measurement and might therefore miss some specificities of dynamic motion. Fluoroscopy-based measurements provide sufficient accuracy for dynamic shoulder analysis [22], but they use ionizing radiation.

The purpose of this chapter was to evaluate the different types of impingement and stability during tennis movements through a new capture system using skin-mounted markers.

MOTION CAPTURE

Intermediate or ex-professional tennis players underwent a MRI shoulder arthrography. Patient-specific 3D models of the shoulder bones (humerus, scapula, clavicle and sternum) were reconstructed using ITK-SNAP software [23]. The tennis players were equipped with spherical retroreflective markers placed directly onto the skin and kinematic data was recorded using a Vicon MX T-Series motion capture system (Vicon, Oxford Metrics, UK) consisting of 24 cameras ($24 \times T40S$) sampling at 120 Hz. They perform the following tennis movements: forehand, backhand, flat and kick serves (**fig. 2**). They were also instructed to perform three motor tasks: internal-external rotation of the arm with 90° abduction and elbow flexed 90° , flexion of the arm from neutral to maximum flexion, and empty-can abduction from neutral to maximum abduction in the scapular plane. Three trials of each motion were recorded. To verify its accuracy, kinematic data was collected simultaneously from an X-ray fluoroscopy unit. The accuracy of the model for glenohumeral orientation was within 4° for each anatomical plane and between 1.9 and 3.3mm in average for glenohumeral translations. Moreover, the results showed that the translations patterns

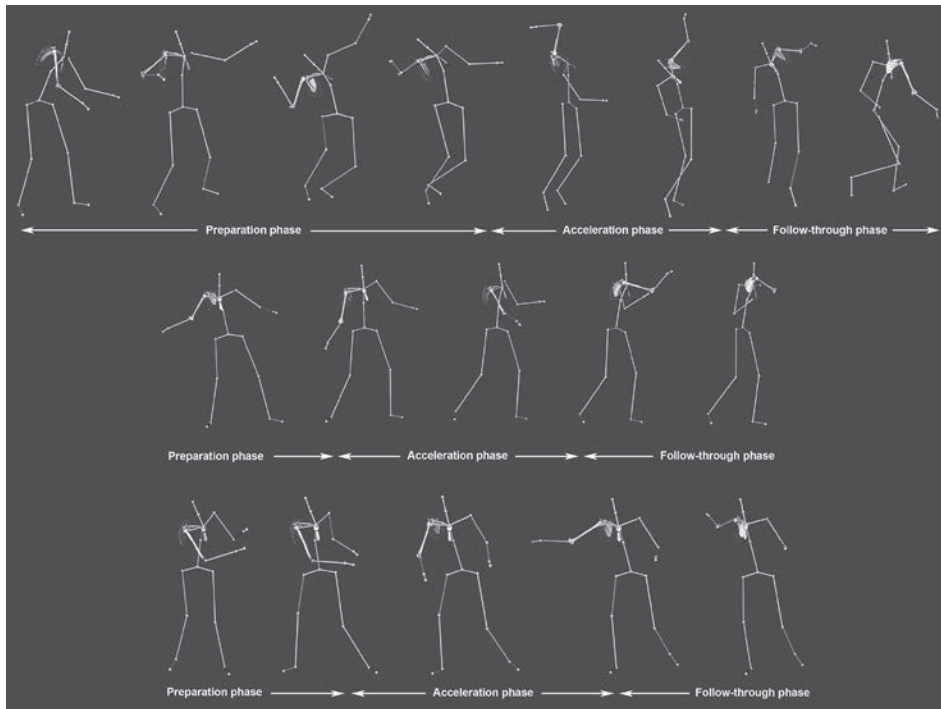


Fig. 2 : Computed tennis positions (here the right shoulder) according to the three main phases, showing the markers setup (small colored spheres) and the virtual skeleton. Top: serve shot. Position 4, 7 and 8 are commonly known as the cocking, deceleration and finish stages, respectively. Middle: forehand shot. Bottom: backhand shot.

and amplitudes computed with the model were in good agreement with previous works [24, 25].

Posterosuperior impingements during the late cocking stage of serve were the most frequent (seven subjects, 75% of the cases).

IMPINGEMENTS EVALUATION

No subcoracoid impingement was detected during the late follow-through phase of forehand and the backhand preparation phase, but anterosuperior impingements were observed in two subjects during forehand (29% of the cases). Anterior and lateral subacromial impingements occurred during the late cocking stage of serve in three and four subjects, respectively.

GLENOHUMERAL MOTION AND STABILITY

In this position, glenohumeral translation was anterior (flat serve, mean: 34%; kick serve, mean: 34%) and superior (flat serve, mean: 12%; kick serve, mean: 13%). During the deceleration stage of serve, anterior and superior translation varied from 8% to 57% and from 5% to 34%, respectively. During the finish stage of serve, anterior translation was slightly

more intense (flat serve, mean: 46%; kick serve, mean: 42%), while superior translation remained low (flat serve, mean: 3%; kick serve, mean: 0%). There were no static posterosuperior shifts of glenohumeral contact point. During abduction, a superior translation of the humeral head in relation to the glenoid was observed until 65° followed by an inferior translation beyond this amplitude. Consequently, lateral and anterior subacromial spaces decreased until 65° and then increased progressively. At rest, the humeral head was slightly anteriorly translated. When flexion began, a posterior translation was remarked until 70° followed by a return to a more anterior translation. There was no posterior subluxation at any degree of flexion. Also, based on the visual assessment of the 3D simulations, we could notice in six subjects that the arm in abduction was beyond the scapular plane during the cocking stage of serve, resulting in hyperextension.

DISCUSSION

Shoulder pain and lesions are common in overhead athletes [1, 26-28]. In the present study, 90% of tennis players presented radiographic signs of structural lesions that could be related to impingement syndrome due to overhead arm movements. However, the precise causes for these lesions remain unclear. It might result from different factors (e.g., repetitive contact, subtle glenohumeral instability, torsional overload with repetitive hypertwisting, scapular orientation and dyskinesis, etc.). The theory of internal impingement in overhead athletes, which occurs with the arm in the cocked position of 90° abduction, full

external rotation and extension [29], holds that repeated contacts between the rotator cuff insertion and the posterosuperior glenoid rim lead to articular-sided partial thickness rotator cuff tears and superior labral lesions [10, 13, 29-31]. If the contact is physiologic [10, 30, 32-34] repetitive contacts that are applied at a rate exceeding tissue repair [35] or torsional and shear stresses [18] may be responsible for rotator cuff or labral damages.

Anterosuperior and subacromial impingements remained occasional in this particular population. No shoulder instability could be noted during tennis movements. However, posterosuperior impingement was frequent when serving. As expected, this shot seems thus to be the most harmful for the tennis player's shoulder. Regarding this type of impingement, Gilles Walch's and Christopher Jobe's theories of repetitive contact could be the cause of posterior and posterosuperior labral lesions, as well as PASTA lesions of the posterosuperior cuff [10, 30]. Indeed, we were not able, as other authors [33], to confirm the role in the impingement development of other culprits like **1)** static posterosuperior shifts of glenohumeral contact point leading to torsional overload [18], or **2)** Frank Jobe's instability because of gradual repetitive stretching of the anterior capsuloligamentous structures [13, 29, 30]. Nevertheless, this could be explained by the fact that there are many kinds of overhead athletes, and tennis players do not have same external rotation in abduction and arm's velocity as, for example, baseball throwing players that have previously been studied. In addition, this could also reflect efficiency of prevention program that has been established in tennis clubs.

Concerning subacromial impingement during abduction, a superior translation of the humeral head in relation to the glenoid was observed followed by an inferior translation beyond 65°. Such superior and inferior translations confirm previous observations [24, 25, 36, 37]. Consequently, subacromial space decreased until 65° and then increased progressively. Anterior [4] and lateral [5] impingements could hence occur at the beginning of abduction and not at or above 90° like previously believed [38].

Regarding motion of the glenohumeral joint, the range in internal and external rotation should remain constant between the dominant and the non-dominant arm, with a shift in the external rotation sector of the dominant arm in overhead throwers [18]. We could neither confirm the rotational 180° rule (fig. 3) in tennis players, as the mean values of the ROM

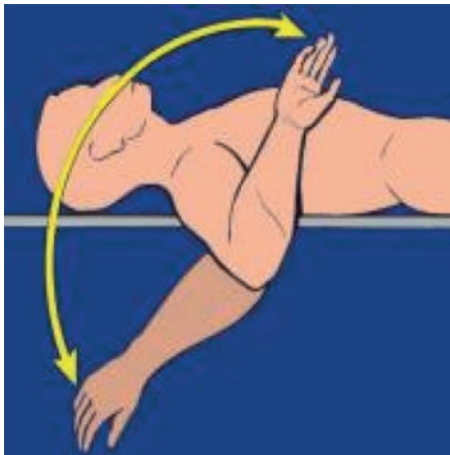


Fig. 3 : The 180° rotational rule: the ROM in rotation is supposed to be constant, around 180°. However, the present study found mean ROM around 96°.

computed in this study were around twice smaller. Similar measurements were found in handball players [39]. We are therefore not persuaded that contracted posterior band, evoking posterior cable shortens with resultant GIRD, is a theory that can be extrapolated in tennis players and might be specific to baseball.

Finally, we also evaluated posterior humeral head translation in relation to the glenoid during flexion. An hypothesis to the development of posterior static subluxation described by Walch *et al.* [40] could be posterior subluxation during normal anterior elevation. At rest, the humeral head was slightly anteriorly translated. When forward flexion began, a slight posterior translation was remarked until 70° followed by a return to a more anterior translation. There was no posterior subluxation at any degree of flexion. Therefore, since no dynamic and physiologic posterior instability was observed, it is probably not responsible at term for a static instability in these subjects without hyperlaxity.

CONCLUSION

Tennis players presented frequent radiographic signs of structural lesions that could be mainly related to posterosuperior impingements due to repetitive abnormal motion contacts. These observations offers novel insights into the analysis of shoulder impingement and instability that could, with future studies, be generalized to other shoulder pathologies and sports. This original method may open new horizons leading to improvement in impingement comprehension.

REFERENCES

- [1] ABRAMS GD, RENSTROM PA, SAFRAN MR. Epidemiology of musculoskeletal injury in the tennis player. *Br J Sports Med.* 2012; 46(7): 492-8.
- [2] COOLS AM, DECLERCQ G, CAGNIE B, CAMBIER D, WITVROUW E. Internal impingement in the tennis player: rehabilitation guidelines. *Br J Sports Med.* 2008; 42(3): 165-71.
- [3] MANSKE RC, GRANT-NIERMAN M, LUCAS B. Shoulder posterior internal impingement in the overhead athlete. *International journal of sports physical therapy.* 2013; 8(2): 194-204.
- [4] NEER CS 2nd. Anterior acromioplasty for the chronic impingement syndrome in the shoulder: a preliminary report. *J Bone Joint Surg Am.* 1972; 54(1): 41-50.
- [5] NYFFELER RW, WERNER CM, SUKTHANKAR A, SCHMID MR, GERBER C. Association of a large lateral extension of the acromion with rotator cuff tears. *J Bone Joint Surg Am.* 2006; 88(4): 800-5.
- [6] WATSON-JONES R. Fractures and Other Bone and Joint Injuries. *Baltimore: Williams & Wilkins; 1940.*
- [7] DENARD PJ, LÄDERMANN A, BURKHART SS. Arthroscopic management of subscapularis tears. *Sports medicine and arthroscopy review.* 2011; 19(4): 333-41.
- [8] GERBER C, TERRIER F, GANZ R. The role of the coracoid process in the chronic impingement syndrome. *J Bone Joint Surg Br.* 1985; 67(5): 703-8.
- [9] MARTETSCHLAGER F, RIOS D, BOYKIN RE, GIPHART JE, DE WAHA A, MILLETT PJ. Coracoid impingement: current concepts. *Knee Surg Sports Traumatol Arthrosc.* 2012; 20(11): 2148-55.
- [10] WALCH G, BOILEAU P, NOEL E, DONELL ST. Impingement of the deep surface of the supraspinatus tendon on the posterosuperior glenoid rim: An arthroscopic study. *J Shoulder Elbow Surg.* 1992; 1(5): 238-45.
- [11] GERBER C, SEBESTA A. Impingement of the deep surface of the subscapularis tendon and the reflection pulley on the anterosuperior glenoid rim: a preliminary report. *J Shoulder Elbow Surg.* 2000; 9(6): 483-90.
- [12] HABERMEYER P, MAGOSCH P, PRITSCH M, SCHEIBEL MT, LICHTENBERG S. Anterosuperior impingement of the shoulder as a result of pulley lesions: a prospective arthroscopic study. *J Shoulder Elbow Surg.* 2004; 13(1): 5-12.
- [13] JOBE CM. Posterior superior glenoid impingement: expanded spectrum. *Arthroscopy.* 1995; 11(5): 530-6.
- [14] COOLS AM, CAMBIER D, WITVROUW EE. Screening the athlete's shoulder for impingement symptoms: a clinical reasoning algorithm for early detection of shoulder pathology. *Br J Sports Med.* 2008; 42(8): 628-35.
- [15] OKORO T, REDDY VR, PIMPELNARKAR A. Coracoid impingement syndrome: a literature review. *Current reviews in musculoskeletal medicine.* 2009; 2(1): 51-5.
- [16] BURKHART SS, MORGAN CD, KIBLER WB. The disabled throwing shoulder: spectrum of pathology Part III: The SICK scapula, scapular dyskinesis, the kinetic chain, and rehabilitation. *Arthroscopy.* 2003; 19(6): 641-61.
- [17] TIMMONS M, LOPES-ALBERS AD, BORGS MILLER L, ZIRKER C, ERICKSEN J, MICHENER L. Differences in scapular orientation, subacromial space and shoulder pain between the full can and empty can tests. *Clin Biomech.* 28: Elsevier; 2013. p. 395-401.
- [18] BURKHART SS, MORGAN CD, KIBLER WB. The disabled throwing shoulder: spectrum of pathology Part I: pathoanatomy and biomechanics. *Arthroscopy.* 2003; 19(4): 404-20.
- [19] RIAND N, LEVIGNE C, RENAUD E, WALCH G. Results of derotational humeral osteotomy in posterosuperior glenoid impingement. *Am J Sports Med.* 1998; 26(3): 453-9.
- [20] RIAND N, BOULAHIA A, WALCH G. [Posterosuperior impingement of the shoulder in the athlete: results of arthroscopic debridement in 75 patients]. *Rev Chir Orthop Reparatrice Appar Mot.* 2002; 88(1): 19-27.
- [21] LEVIGNE C, GARRET J, GROSCLAUDE S, BOREL F, WALCH G. Surgical technique arthroscopic posterior glenoidplasty for posterosuperior glenoid impingement in throwing athletes. *Clin Orthop Relat Res.* 2012; 470(6): 1571-8.
- [22] ZHU Z, MASSIMINI DF, WANG G, WARNER JJ, LI G. The accuracy and repeatability of an automatic 2D-3D fluoroscopic image-model registration technique for determining shoulder joint kinematics. *Medical engineering & physics.* 2012; 34(9): 1303-9.

- [23] YUSHKEVICH PA, PIVEN J, HAZLETT HC, SMITH RG, HO S, GEE JC, *et al.* User-guided 3D active contour segmentation of anatomical structures: significantly improved efficiency and reliability. *NeuroImage*. 2006; 31(3): 1116-28.
- [24] MASSIMINI DF, BOYER PJ, PAPANNAGARI R, GILL TJ, WARNER JP, LI G. *In-vivo* glenohumeral translation and ligament elongation during abduction and abduction with internal and external rotation. *Journal of orthopaedic surgery and research*. 2012; 7: 29.
- [25] MATSUKI K, MATSUKI KO, YAMAGUCHI S, OCHIAI N, SASHO T, SUGAYA H, *et al.* Dynamic *in vivo* glenohumeral kinematics during scapular plane abduction in healthy shoulders. *The Journal of orthopaedic and sports physical therapy*. 2012; 42(2): 96-104.
- [26] BEITZEL K, BEITZEL KI, ZANDT JF, BUCHMANN S, SCHWIRTZA, IMHOFF AB, *et al.* Premature cystic lesions in shoulders of elite junior javelin and volleyball athletes: a comparative evaluation using 3.0 Tesla MRI. *J Shoulder Elbow Surg*. 2013; 22(6): 792-9.
- [27] BRAUN S, KOKMEYER D, MILLETT PJ. Shoulder injuries in the throwing athlete. *J Bone Joint Surg Am*. 2009; 91(4): 966-78.
- [28] CONNOR PM, BANKS DM, TYSON AB, COUMAS JS, D'ALESSANDRO DF. Magnetic resonance imaging of the asymptomatic shoulder of overhead athletes: a 5-year follow-up study. *Am J Sports Med*. 2003; 31(5): 724-7.
- [29] DAVIDSON PA, ELATTRACHE NS, JOBE CM, JOBE FW. Rotator cuff and posterior-superior glenoid labrum injury associated with increased glenohumeral motion: a new site of impingement. *J Shoulder Elbow Surg*. 1995; 4(5): 384-90.
- [30] JOBE CM. Superior glenoid impingement. Current concepts. *Clin Orthop Relat Res*. 1996(330): 98-107.
- [31] MEISTER K. Internal impingement in the shoulder of the overhand athlete: pathophysiology, diagnosis, and treatment. *American journal of orthopedics*. 2000; 29(6): 433-8.
- [32] BARBER FA, MORGAN CD, BURKHART SS, JOBE CM. Current Controversies. Point counterpoint. Labrum/biceps/cuff dysfunction in the throwing athlete. *Arthroscopy*. 1999; 15(8): 852-7.
- [33] HALBRECHT JL, TIRMAN P, ATKIN D. Internal impingement of the shoulder: comparison of findings between the throwing and nonthrowing shoulders of college baseball players. *Arthroscopy*. 1999; 15(3): 253-8.
- [34] McFARLANDEG, HSU CY, NEIRAC, O'NEIL O. Internal impingement of the shoulder: a clinical and arthroscopic analysis. *J Shoulder Elbow Surg*. 1999; 8(5): 458-60.
- [35] KVITNE RS, JOBE FW, JOBE CM. Shoulder instability in the overhand or throwing athlete. *Clinics in sports medicine*. 1995; 14(4): 917-35.
- [36] FAVARD L, DESPERIEZ M, ALISON D. Kinematics of anterior elevation in the normal shoulder. In: Walch G, Boileau P, editors. *Shoulder Arthroplasty*. Berlin: Springer; 1999. p. 23-7.
- [37] KARDUNA AR, WILLIAMS GR, WILLIAMS JL, IANNOTTI JP. Glenohumeral joint translations before and after total shoulder arthroplasty. A study in cadavera. *J Bone Joint Surg Am*. 1997; 79(8): 1166-74.
- [38] HARRISON AK, FLATOW EL. Subacromial impingement syndrome. *J Am Acad Orthop Surg*. 2011; 19(11): 701-8.
- [39] ALMEIDA GP, SILVEIRA PF, ROSSETO NP, BARBOSA G, EJNISMAN B, COHEN M. Glenohumeral range of motion in handball players with and without throwing-related shoulder pain. *J Shoulder Elbow Surg*. 2013; 22(5): 602-7.
- [40] WALCH G, ASCANI C, BOULAHIAA, NOVE-JOSSERAND L, EDWARDS TB. Static posterior subluxation of the humeral head: an unrecognized entity responsible for glenohumeral osteoarthritis in the young adult. *J Shoulder Elbow Surg*. 2002; 11(4): 309-14.

